

## AORTIC ANEURYSM

Muhammad Naeem Shahid  
Shahid Muhammad Nadeem

SamSMU

Assistant Professor of Human Anatomy Department

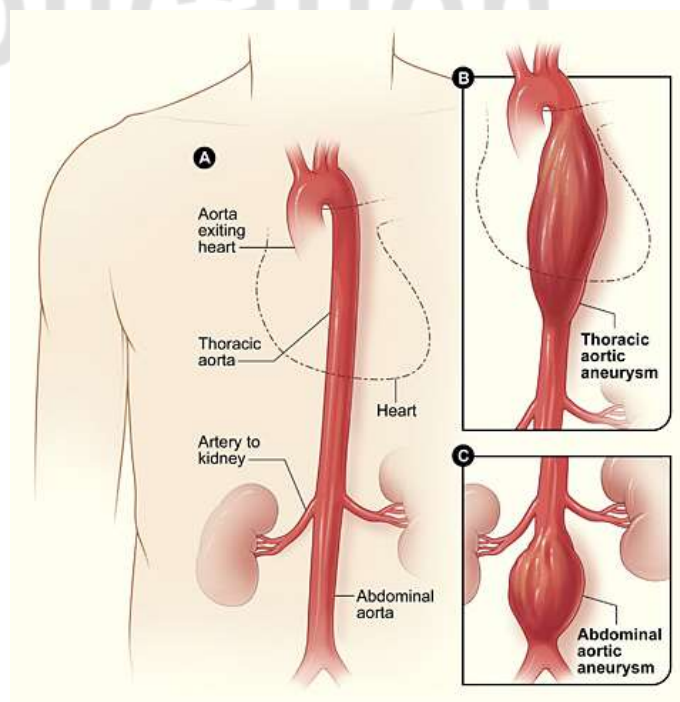
**Annotation:** An aortic aneurysm is a localized dilation of the aorta, the largest artery in the body, which can lead to life-threatening complications if ruptured. It most commonly occurs in the abdominal or thoracic region and may be asymptomatic until an acute event occurs. Risk factors include hypertension, smoking, genetic predisposition, and age. Diagnostic imaging such as ultrasound, CT, or MRI plays a critical role in detecting and monitoring aneurysms. Treatment options vary from careful monitoring to surgical intervention, depending on the size and growth rate of the aneurysm. Advances in endovascular techniques have significantly improved outcomes for high-risk patients. This paper reviews the pathophysiology, diagnostic methods, and management strategies for aortic aneurysms, highlighting the importance of early detection and individualized care.

**Keywords:** Aortic aneurysm, abdominal aortic aneurysm (AAA), thoracic aortic aneurysm (TAA), aneurysm rupture, endovascular repair, vascular surgery, imaging diagnostics, cardiovascular risk, screening, hypertension.

Aortic aneurysms are balloon-like bulges that occur in the aorta, the main artery carrying oxygen-rich blood to your body. The aorta has thick walls that stand up to normal blood pressure. However, certain medical problems, genetic conditions, and trauma can damage or weaken these walls.

Aortic aneurysms result from a weakness in the wall of the aorta and increase the risk of aortic rupture. When rupture occurs, massive internal bleeding results and, unless treated immediately, shock and death can occur. One review stated that up to 81% of people having abdominal aortic aneurysm rupture will die, with 32% dying before reaching a hospital.<sup>[6]</sup>

According to a review of global data through 2019, the prevalence of abdominal aortic aneurysm worldwide was about 0.9% in people under age 79 years, and is about four times higher in men than in women at any age.<sup>[4]</sup> Death occurs in about 55-



64% of people having rupture of the AAA.<sup>[4]</sup>

Screening with ultrasound is indicated in those at high risk. Prevention is by decreasing risk factors, such as smoking, and treatment is either by open or endovascular surgery. Aortic aneurysms resulted in about 152,000 deaths worldwide in 2013, up from 100,000 in 1990.

### **CLASSIFICATION**

Aortic aneurysms are classified by their location on the aorta.

An aortic root aneurysm, or aneurysm of the sinus of Valsalva.

Thoracic aortic aneurysms are found within the chest; these are further classified as ascending, aortic arch, or descending aneurysms.

Abdominal aortic aneurysms, "AAA" or "Triple A", the most common form of aortic aneurysm, involve that segment of the aorta within the abdominal cavity. Thoracoabdominal aortic aneurysms involve both the thoracic and abdominal aorta.

Thoracoabdominal aortic aneurysms comprise some or all of the aorta in both the chest and abdomen, and have components of both thoracic and abdominal aortic aneurysms.[8] The Crawford classification describes five types.

### **ABDOMINAL AORTIC ANEURYSM**

Abdominal aortic aneurysms (AAAs) are more common than their thoracic counterpart. One reason for this is that elastin, the principal load-bearing protein present in the wall of the aorta, is reduced in the abdominal aorta as compared to the thoracic aorta. Another is that the abdominal aorta does not possess vasa vasorum, the nutrient-supplying blood vessels within the wall of the aorta. Most AAA are true aneurysms that involve all three layers (tunica intima, tunica media and tunica adventitia). The prevalence of AAAs increases with age, with an average age of 65–70 at the time of diagnosis. AAAs have been attributed to atherosclerosis, though other factors are involved in their formation.[8] Risk factors for AAA include the male gender, aging, a history of smoking, hypercholesterolemia, and hypertension.[4][8] Reviews reported estimates for prevalence rates of AAA were 0.9-9% in men and 1–2% in women, where, generally, the incidence of AAA is four times greater in men compared to women at the same age.[4][8]

CT reconstruction image of an abdominal aortic aneurysm

The risk of rupture of an AAA is related to its diameter; once the aneurysm reaches about 5 cm, the yearly risk of rupture may exceed the risks of surgical repair for an average-risk patient. Rupture risk is also related to shape; so-called "fusiform" (long) aneurysms are considered less rupture-prone than "saccular" (shorter, bulbous) aneurysms, the latter having more wall tension in a particular location in the aneurysm wall.

The prevalence of AAA worldwide in 2019 was about 0.9% in people under age 79 years,[4] whereas a 2014 review reported a range of 2-12%, occurring in about 8% of men more than 65 years of age. Men are about four times more likely to have AA compared to women at any age, with death occurring in about 55-64% of people having AAA rupture.[4]

Before rupture, an AAA may present as a large, pulsatile mass above the umbilicus. A bruit may be heard from the turbulent flow in the aneurysm. Rupture may be the first sign of

AAA. Once an aneurysm has ruptured, it presents with classic symptoms of abdominal pain which is severe, constant, and radiating to the back.

The diagnosis of an abdominal aortic aneurysm can be confirmed by the use of ultrasound. Rupture may be indicated by the presence of free fluid in the abdomen. A contrast-enhanced abdominal CT scan is the best test to diagnose an AAA and guide treatment options.

## **SURGERY**

Decisions about repairing an aortic aneurysm are based on the balance between the risk of aneurysm rupture without treatment versus the risks of the treatment itself. For example, a small aneurysm in an elderly patient with severe cardiovascular disease would not be repaired. The chance of the small aneurysm rupturing is overshadowed by the risk of cardiac complications from the procedure to repair the aneurysm.

The risk of the repair procedure is two-fold. First, there is consideration of the risk of problems occurring during and immediately after the procedure itself ("peri-procedural" complications). Second, the effectiveness of the procedure must be taken into account, namely whether the procedure effectively protects the patient from aneurysm rupture over the long term, and whether the procedure is durable so that secondary procedures, with their attendant risks, are not necessary over the life of the patient. A less invasive procedure (such as endovascular aneurysm repair) may be associated with fewer short-term risks to the patient (fewer peri-procedural complications) but secondary procedures may be necessary over long-term follow-up.

The determination of surgical intervention is determined on a per-case basis. The diameter of the aneurysm, its rate of growth, the presence or absence of Marfan syndrome, Ehlers–Danlos syndromes or similar connective tissue disorders, and other co-morbidities are all important factors in the overall treatment.

A large, rapidly expanding, or symptomatic aneurysm should be repaired, as it has a greater chance of rupture. Slowly expanding aortic aneurysms may be followed by routine diagnostic testing (i.e.: CT scan or ultrasound imaging).

## **CONCLUSION**

Aortic aneurysms represent a significant health concern due to their potential for sudden rupture and high mortality rates. Early diagnosis through routine screening in at-risk populations, combined with advances in surgical and endovascular treatment, can significantly improve patient outcomes. Continued research and public health awareness are essential for optimizing management and reducing aneurysm-related deaths.

## **REFERENCES:**

1. Song P, He Y, Adeloye D, et al. (June 2023). "The Global and Regional Prevalence of Abdominal Aortic Aneurysms: A Systematic Review and Modeling Analysis". *Annals of Surgery*. **277** (6): 912–919. doi:10.1097/SLA.0000000000005716. PMC 10174099. PMID 36177847

2. Mathur A, Mohan V, Ameta D, Gaurav B, Haranahalli P (April 2016). "Aortic aneurysm". *Journal of Translational Internal Medicine*. 4 (1): 35–41. doi:10.1515/jtim-2016-0008. PMC 5290913
3. Бурхонова, Ш. И., Негмаджанов, Б. Б., Раббимова, Г. Т., & Валиев, Ш. Н. (2020). Сравнительная оценка некоторых результатов операций с применением нижнесрединного разреза и доступа по Joel-Cohen в неотложной акушерской практике. *Достижения науки и образования*, (3 (57)), 79-83.
4. Валиев, Ш. Н., & Негмаджанов, Б. Б. СЛУЧАЙ ПОСЛЕОПЕРАЦИОННОГО МОЛНИЕНОСНОГО СЕПТИЧЕСКОГО ШОКА, ВЫЗВАННОГО АНАЭРОБНОЙ ИНФЕКЦИЕЙ У ЖЕНЩИНЫ С АУТОИММУННЫМ ГЕПАТИТОМ. *JOURNAL OF REPRODUCTIVE HEALTH AND URO-NEPHROLOGY RESEARCH*, 50.
5. Valiyev, S. CHANGES IN WATER HOLDING CAPACITY OF ARTEMISIA DIFFUSA IN THE CONDITION OF DIFFERENT SHEEP GRAZING INTENSITIES.
6. Шухрат Насимович Валиев. (2024). ЭФФЕКТИВНОСТЬ ОПЕРАЦИЙ КЕСАРЕВА СЕЧЕНИЯ В ЗАВИСИМОСТИ ОТ ОПЕРАЦИОННОГО ДОСТУПА В ЭКСТРЕННЫХ СИТУАЦИЯХ. *TADGIQOTLAR.UZ*, 51(5), 120-124.
7. УЗБЕКИСТАН, Р. *JOURNAL OF REPRODUCTIVE HEALTH AND URO-NEPHROLOGY RESEARCH*.
8. Бурхонова, Ш. И., Негмаджанов, Б. Б., Раббимова, Г. Т., & Валиев, Ш. Н. (2020). Сравнительная оценка некоторых результатов операций с применением нижнесрединного разреза и доступа по Joel-Cohen в неотложной акушерской практике. *Достижения науки и образования*, (3 (57)), 79-83.
9. Erkinovna, S. D. (2025). BUXORO ADABIY MUHITIDA MUSIQA ILMINING O ‘QITILISHI. Introduction of new innovative technologies in education of pedagogy and psychology, 2(2), 64-69.
10. Saidova, D. E. (2024, August). ACTIVITIES OF THE JADIDS IN THE FIELD OF MUSICAL EDUCATION AND EDUCATION. In *INTERDISCIPLINE INNOVATION AND SCIENTIFIC RESEARCH CONFERENCE* (Vol. 2, No. 21, pp. 236-246).
11. Erkinovna, S. D. (2025). BUXORO ADABIY MUHITIDA MUSIQAGA OID QARASHLAR (XIX OXIRI XX ASR BOSHLARIDA). Introduction of new innovative technologies in education of pedagogy and psychology, 2(2), 47-52.
12. Muradovich, M. R., & Soomro, N. IMPROVING THE DESIGN OF THE 1XK BRAND CLEANING MACHINE TO PRESERVE THE NATURAL CHARACTERISTICS OF COTTON.